

LETTERS TO THE EDITOR

HER2/Topoisomerase IIa co-amplified breast adenocarcinoma “mirror” cases with different Topoisomerase IIa expression patterns

Dear Editor,

Concerning breast adenocarcinomas, critical genes -including HER2/neu, Topoisomerase IIa (Topo IIa) and estrogen/progesterone receptors- are frequently altered, affecting the biological behavior of the neoplasm and also the response rates to specific targeted or chemotherapeutic agents [1]. Interestingly, HER2 and Topo IIa genes share the same Chr 17 locus (band 17q12-21) and for this reason they are frequently co-amplified (~40-90%) demonstrating different protein expression. Additionally, Chr 17 polysomy combined or not with these genes' amplification seems to be to an independent predictor for anthracycline (a Topo IIa inhibitor) response -as adjuvant chemotherapy- in sub groups of breast cancer cases [2]. In contrast to this, Topo IIa gene deletion is associated with poor prognosis and an aggressive phenotype in the corresponding patients [3].

Two female patients, a 39-year-old and a 46-year-old, were diagnosed with breast cancer in 417 VA Hospital. Surgical resection was performed and pathology showed breast ductal adenocarcinoma grade I and II, respectively based on

WHO breast tumor classification. Fluorescence in situ hybridization (FISH) with a triple color signal (HER2/TopoIIa/CEP17) and immunohistochemical (IHC) analyses were performed in the corresponding tissue sections. Evaluation of gene/protein expression patterns was based on ASCO/ACAP guidelines 2013 [4]. In both of the examined cases, FISH detected combined HER2 & Topo IIa gene amplification. In the first case IHC analysis demonstrated a HER2 score 3+ with a low Topo IIa expression, whereas the second case showed a HER2 score 2+ with high Topo IIa protein expression (Figure 1). Chr 17 demonstrated a normal diploid pattern in both of them. Concerning the oncological approach of the cases, trastuzumab (anti-HER2 monoclonal antibody) and anthracycline (doxorubicin) based chemotherapy was administered. A 2-year follow up showed high response rates for the monoclonal antibody in both of the cases, but differences in anthracycline response were also reported. The first patient did not benefited after the regimen implementation and the chemotherapy was dropped.

Topoisomerase IIa gene alterations -including amplification and deletion- lead to different protein expres-

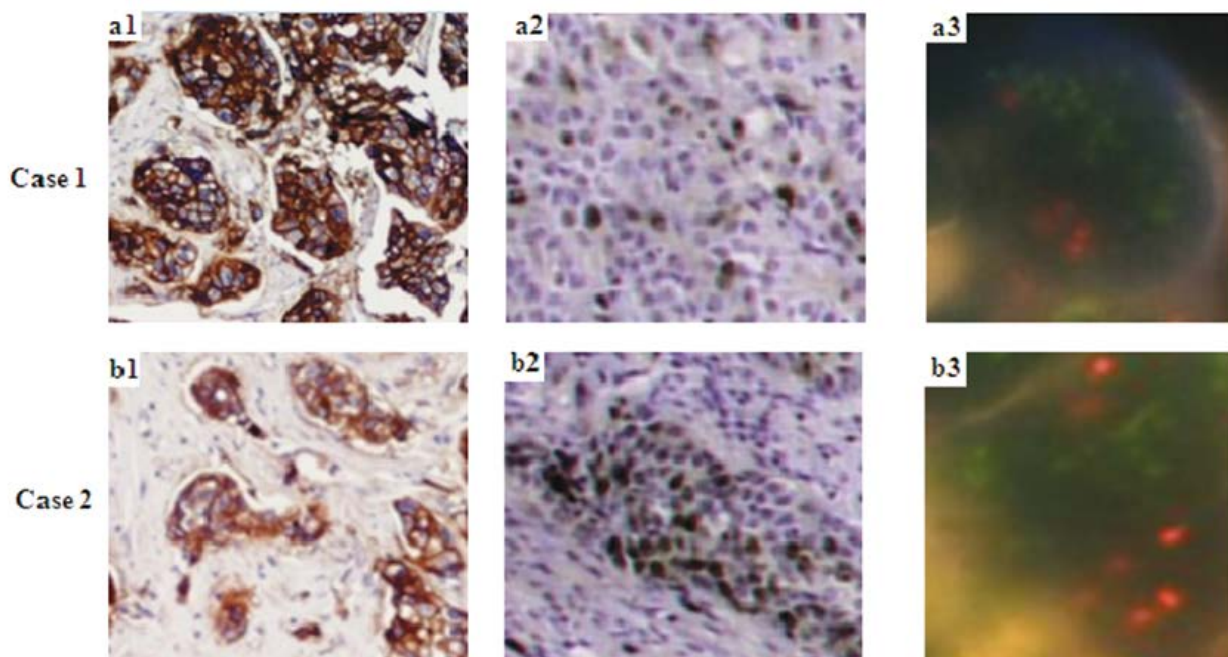


Figure 1. Demonstration of the two analyzed breast ductal adenocarcinoma cases. Case 1 analysis a1-a3: IHC: HER2 score 3+, low Topo IIa expression, and FISH: HER2 & Topo IIa gene coamplification. Case 2 analysis b1-b3: IHC: HER2 score 2+, high Topo IIa expression, and FISH HER2 & Topo IIa gene coamplification (IHC chromogen: DAB; FISH signals: HER2 gene Green, Topo IIa Red, Chr 17 orange (Original magnifications a1-a2 and b1-b2 10x; a3 and b3 60x).

sion patterns in breast adenocarcinomas. HER2/Topo IIa co-amplification is considered as a critical genetic event for applying combined targeted and chemotherapeutic regimens. But, some studies showed that, concerning Topo IIa, not only amplification but predominantly high nuclear/perinuclear staining expression levels are the suitable substrates for increased response rates to anthracycline based chemotherapy implementation. In contrast, negative or low levels of the marker are associated with poor prognosis and an aggressive phenotype [5].

References

1. Pritchard KI, Shepherd LE, O'Malley FP et al. HER2 and responsiveness of breast cancer to adjuvant chemotherapy. *N Engl J Med* 2006;354:2103-2111.
2. Tsiambas E, Georgiannos SN, Salemis N et al. Significance of estrogen receptor 1 (ESR-1) gene imbalances in colon and hepatocellular carcinomas based on tissue microarrays analysis. *Med Oncol* 2011;28:934-940.
3. Kim A, Shin HC, Bae YK et al. Multiplication of Chromosome 17 Centromere Is Associated with Prognosis in Patients with Invasive Breast Cancers Exhibiting Normal HER2 and TOP2A Status. *J Breast Cancer* 2012;15:24-33.
4. Wolff AC, Hammond ME, Hicks DG et al. Recommendations for human epidermal growth factor receptor 2 testing in breast cancer: American Society of Clinical Oncology/College of American Pathologists clinical practice guideline update. *J Clin Oncol* 2013;31:3997-4013.
5. Schindlbeck C, Mayr D, Olivier C et al. Topoisomerase IIalpha expression rather than gene amplification predicts responsiveness of adjuvant anthracycline-based chemotherapy in women with primary breast cancer. *J Cancer Res Clin Oncol* 2010;136:1029-1037.

Evangelos Tsiambas¹, Panagiotis P. Fotiadis², Chrisa Sioka³, Vasileios Ragos⁴

¹Dept of IHC & Mol Biology, 401 GAH, Athens, Greece; ²Dept of Surgery, Leicester General Hospital, UK; ³Dept of Nuclear Medicine- Neurosurgical Research Institute University Hospital of Ioannina, Greece; ⁴Dept of Maxillofacial Surgery, Medical School, University of Ioannina, Greece

Correspondence to: Evangelos Tsiambas, MD, MSc, PhD.
E-mail: tsiambasecyto@yahoo.gr

Regular daily consumption of turmeric may be a complementary agent for the adjuvant treatment of hormone receptor positive breast cancer

Dear Editor,

Turmeric is a plant of the ginger family. It is native to southern Asia and is widely used as a spice in South Asian and Middle Eastern cooking. Curcumin is a yellow chemical, the principal curcuminoid of turmeric. Its potential medicinal properties are not known in detail and are an area of active research [1]. Invasion and metastasis are two important biological mechanisms that may indicate aggressiveness of breast cancer. Natural phospholipid lysophosphatidic acid (LPA) showed important roles in the regulation of proliferation, migration and invasion of cancer cells. Furthermore, LPA was shown to be correlated with the invasive and metastatic characteristics of several cancers including breast cancer [2]. LPA-induced pathways induce RhoA/ROCK/MMP signalling which may be involved in invasion of breast cancer. A recent in vitro study revealed that curcumin inhibits LPA-induced invasion by downregulating RhoA/ROCK/MMPs pathway in hormone receptor-positive MCF7 breast cancer cells [3]. A tumor suppressor Deleted in Liver Cancer 1 (DLC1) has been reported to be downregulated in several kinds of cancer including breast cancer. A recent study showed that curcumin reduces hypermethylation of DLC1 promoter to induce DLC1 expression and inhibits growth of human estrogen receptor-positive MDA-MB-361 breast cancer cell lines [4]. In conclusion, regular daily consumption of turmeric may be a complementary agent for

the adjuvant treatment of hormone receptor-positive breast cancer. More data are needed to confirm this proposal.

References

1. <https://en.wikipedia.org/wiki/Curcumin>
2. Swamydas M, Nguyen D, Allen LD, Eddy J, Dreau D. Progranulin stimulated by LPA promotes the migration of aggressive breast cancer cells. *Cell Commun Adhes* 2011;18:119-130.
3. Sun K, Duan X, Cai H et al. Curcumin inhibits LPA-induced invasion by attenuating RhoA/ROCK/MMPs pathway in MCF7 breast cancer cells. *Clin Exp Med* 2016;16:37-47.
4. Liu Y, Zhou J, Hu Y, Wang J, Yuan C. Curcumin inhibits growth of human breast cancer cells through demethylation of DLC1 promoter. *Mol Cell Biochem* 2016 Nov 10. [Epub ahead of print]

Kadri Altundag, MD.

Hacettepe University Cancer Institute, Department of Oncology, Ankara, Turkey

Correspondence to: Kadri Altundag, MD.
E-mail: altundag66@yahoo.com

What is the optimal treatment of metastatic hepatocellular carcinoma after complete resection; case presentation of ovarian metastasis

Dear Editor,

Hepatocellular carcinoma (HCC) is one of the most common malignancies in the world [1]. It can spread to distant organs via hematogeneous or lymphatic route. The most common metastatic sites are lung, intra-abdominal lymph nodes and bone [2]. Ovarian metastasis of HCC is extremely rare, with only a few cases reported in the literature.

Metastasis of HCC still remains as a problem despite many new treatment modalities. Sorafenib has been demonstrated to improve overall survival in patients with advanced HCC in two randomized, double-blinded, placebo-controlled trials [3,4]. However, there is no consensus about the optimal treatment of metastatic HCC after complete resection. Herein we present a case of HCC with ovarian metastasis. In this case the distant metastatic masses were completely resected and no recurrence was seen ever after.

A 27-year-old woman was diagnosed with HCC due to hepatitis B infection 8 years ago. In her first presentation in 2008, she had a solitary 9x6.5 cm mass in the right hepatic lobe without locoregional or distant spread. She had right hepatectomy and cholecystectomy. After 1 year, she had biochemical and clinical recurrence with a 1 cm lesion in the left hepatic lobe. Transarterial chemoembolisation (TACE) was performed and complete resection was achieved. In 2011, a local recurrence near the hepatic vein was detected. The localization of the new lesion was not suitable for TACE, so percutaneous radiofrequency ablation was performed with excellent result. A 5-year follow up was uneventful with no local recurrence or distant metas-

tasis. In the routine follow up in January 2016, pelvic MRI demonstrated a 32x29 mm solid mass in the right ovary and 23x16 mm solid mass in the left ovary. PET/CT showed hypermetabolism in both ovarian masses and no uptake in the liver. Bilateral salpingo-oophorectomy and multiple peritoneal biopsies were performed. Pathologic examination showed HCC metastasis in both ovaries. Surgical margins were negative (R0 resection). Benign cytology on peritoneal specimens was noted. Control imaging studies were negative for disease. The patient's ECOG performance status is 0 and she is just on follow up since the operation.

In a review of the international literature we found few HCC cases metastasized to ovaries, who had R0 resection without any further treatment (Table 1). However, in many of these cases, sorafenib was not available or approved to treat advanced HCC. Today, many guidelines recommend using sorafenib in patients with extra hepatic metastases, whose Child-Pugh Class is A or B. However, no actual controlled studies exist in relation to ovarian metastases.

In conclusion, our experience in this case could suggest close follow up of patients who had R0 resection of ovarian metastasis from HCC.

References

1. Dhanasekaran R, Limaye A, Cabrera R. Hepatocellular carcinoma: current trends in worldwide epidemiology, risk factors, diagnosis, and therapeutics. *Hep Med Evid Res* 2012;4:19-37.
2. Aino H, Sumie S, Niizeki T et al. Clinical characteristics and prognostic factors for advanced hepatocellular carcinoma with extrahepatic metastasis. *Mol Clin Oncol*

Table 1. Characteristics of HCC patients who underwent R0 resection of ovarian metastases

Case no.	PMID or PCMID number- First author	Age (years)	Metastatic site	Previous treatment	Other metastatic sites	Treatment
1	10189033- Khunamornpong S	56	Left ovary	No	Peritoneum	TAH+BSO, sigmoid colostomy
2	10767521- de Groot ME	47	Right ovary	LT	No	BSO
3	1314779- Young RH	38	Left ovary	RH	No	TAH+BSO
4	1314779- Young RH	31	Both ovaries	No	No	BSO
5	1314779- Young RH	68	Left ovary	No	Peritoneum, Para-aortic lymph nodes	BSO, omentectomy
6	6191570- Oortman EH	36	Left ovary	RH	No	TAH+BSO
7	index case	27	Both ovaries	RH, TACE, RFA	No	TAH+BSO

PMID: Pubmed identifier, PCMID: PubMed Central Identifier, LT: Liver transplantation, RH: Right hepatectomy, TACE: Transarterial chemoembolization, RFA: Radiofrequency ablation, TAH: Total abdominal hysterectomy, BSO: Bilateral salpingo-oophorectomy

2014;2:393-398.

3. Llovet JM, Ricci S, Mazzaferro V et al. SHARP Investigators Study Group: Sorafenib in advanced hepatocellular carcinoma. *N Engl J Med* 2008;359:378-390.
4. Cheng AL, Kang YK, Chen Z et al. Efficacy and safety of sorafenib in patients in the Asia-Pacific region with advanced hepatocellular carcinoma: a phase III randomised, double-blind, placebo-controlled trial. *Lancet Oncol* 2009;10:25-34.
5. NCCN Clinical Practice Guidelines in Oncology, Hepatobiliary Cancers. 2016, version 1. <https://www.nccn.org/>

professionals/physician_gls/pdf/hepatobiliary.pdf.

Ibrahim Cil¹, Alisan Zirtiloglu¹, Mehmet Fatih Velibeyoglu², Deniz Tural¹

¹Department of Medical Oncology, Bakirkoy Dr. Sadi Konuk Education and Research Hospital, Istanbul; ²Department of Internal Medicine, Bakirkoy Dr. Sadi Konuk Education and Research Hospital, Istanbul, Turkey

Correspondence to: Deniz Tural, MD.
E-mail: deniztural@gmail.com

Pregnancy-associated immunosuppression necessitates increased vigilance in the differential diagnosis of nasal obstruction

Dear Editor,

We recently came across the case of a 27-year-old pregnant woman, with rapidly progressive symptoms of headache, right-sided nasal obstruction and ipsilateral diplopia, at the 24th week of gestation. Flexible naso-endoscopy revealed an obstructive mass in the right nasal cavity, whilst neck examination was not suggestive of any palpable lymph nodes. Ophthalmology review revealed right exophthalmos, and ophthalmoplegia involving the right medial and superior rectus muscles, as well as the superior oblique, suggestive of right cranial nerve III and IV involvement.

Sinus MRI and CT scans revealed an irregular 38x86x48mm space-occupying lesion, predominantly in the right nasal cavity, extending upwards through the cribriform plate and into the sphenoid sinus; positive right-sided lymph nodes were also identified. The patient was advised to undergo an endoscopic examination under anaesthesia and biopsy, as her symptoms were deteriorating, despite a recent biopsy result suggestive of pyogenic granuloma. The procedure was uneventful both for the mother and the foetus. Histopathology showed high grade undifferentiated sino-nasal carcinoma (SNUC), characterized by sheets of medium-sized undifferentiated polygonal cells, exhibiting cellular pleomorphism, high nuclear to cytoplasmic ratio, necrosis and vascular invasion (Figure 1a). Immunohistochemistry strongly expressed cytokeratins CK8/18+ and CK5-, and weakly expressed EMA. The proliferation index was high, with almost 98% of tumour cells expressing Ki67 (Figure 1b).

A multidisciplinary oncology team suggested that the patient be operated in week 30 of gestation, following a cesarean section delivery. The patient underwent cranio-

facial resection of the SNUC via an extended Lynch-Weber-Ferguson incision followed by chemoradiotherapy. Intraoperatively, the tumour was found to invade the orbital periosteum, not protruding into the orbit, and also progressed into the skull base not invading the dura. It was completely removed within healthy margins. The ensuing orbital defect was repaired with titanium mesh, whilst fascia lata and vastus lateralis free flap were used to repair the skull base. A right level I-IV neck dissection was also performed, revealing a single level IIa infiltrated node, without any extracapsular spread. The patient subsequently received IMRT with concomitant cisplatin chemotherapy [1,2]. She remains a disease-free mother of a healthy child at 2 years follow-up.

SNUC is a rare tumor with only a few cases being reported in the literature, commonly males in their sixth decade [3], and no reported case during pregnancy. Whilst our patient presented with symptoms of a space-occupying lesion, she denied more commonly reported complaints of nasal malignancies, such as epistaxis, rhinorrhea, and facial pain. This atypical presentation calls for the inclusion of broader criteria in the differential diagnosis of nasal masses during pregnancy.

Pregnancy is associated with immunosuppression and enhanced immune tolerance, necessary for the survival of the foetus. However, the CD4+/CD25 cells which promote immune tolerance in pregnancy are also elevated in cancer, and may, hence, be involved in effector T-lymphocyte suppression, decreased anti-tumour immunity, and increased tumour vascularity [4]. Whilst the etiology of SNUC remains largely unknown, the aforementioned physiological changes in pregnancy, along with hormonal and metabolic alterations, may precipitate neoplasm formation within organs such as the sinonasal tract [5].

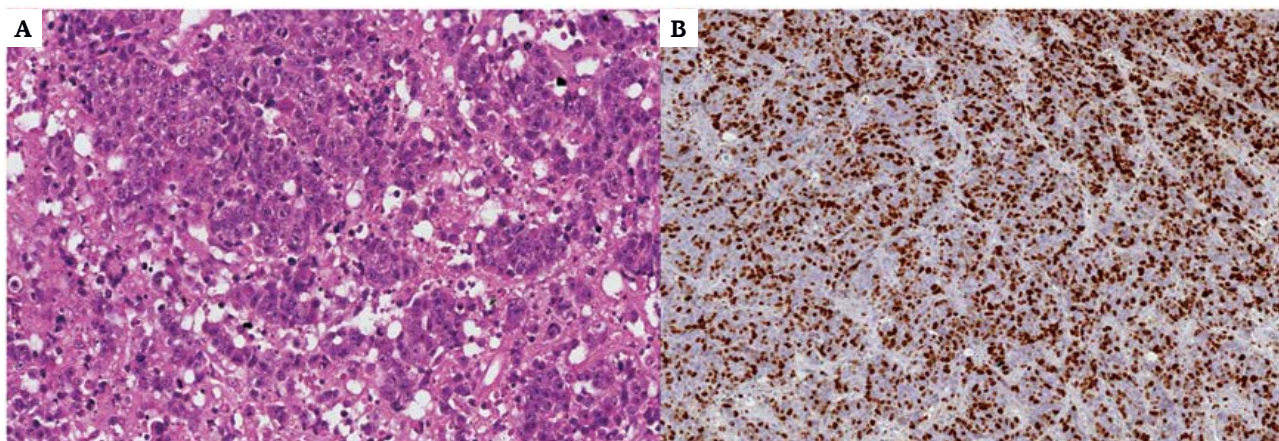


Figure 1. A: Poorly differentiated malignant neoplasm, composed of epithelioid cells with atypical nuclei, presenting prominent nucleoli and frequent mitotic figures (H-E stain x 100). **B:** Almost 98% of the neoplastic cells are expressing Ki-67 (Ki67 immune-labelling x 100).

Acknowledgements

The authors would like to thank Georgios Nakos, MD, Consultant Histopathologist, at the Histopathology Laboratory of Nicosia General Hospital, for the kind provision of the microphotographs.

References

1. Khan MN, Konuthula N, Parasher A et al. Treatment modalities in sinonasal undifferentiated carcinoma: an analysis from the national cancer database. *Int Forum Allergy Rhinol* 2016, Oct 7. [Epub ahead of print]
2. Chambers KJ, Lehmann AE, Remenschneider A et al. Incidence and survival patterns of sinonasal undifferentiated carcinoma in the United States. *J Neurol Surg B Skull Base*. 2015;76:94-100.
3. Ejaz A, Wenig BM. Sinonasal undifferentiated carcinoma: clinical and pathologic features and a discussion on

classification, cellular differentiation, and differential diagnosis. *Adv Anat Pathol* 2005;12:134-143.

4. Driscoll MS, Martires K, Bieber AK, Pomeranz MK, Grant-Kels JM, Stein JA. Pregnancy and melanoma. *J Am Acad Dermatol* 2016;75:669-678.
5. Vladareanu R, Safta D, Bucan L, Zvanca M, Enachescu C, Miron C. Ethmoid sinus carcinoma during pregnancy. *J Clin Med* 2006;1:69-74.

Vanessa Nassour¹, Giannis Thrasylvoulou², Adnan Hubraq¹, Petros V. Vlastarakos³

¹St. George's University of London at the University of Nicosia, Nicosia, Cyprus; ²ENT Dept., Nicosia General Hospital, Nicosia, Cyprus; ³ENT Dept., "Mitera" Infirmary, Athens, Greece

Correspondence to: Petros V. Vlastarakos, MD, MS PhD, IDO-HNS (Eng), E-mail: pevlast@hotmail.com

Coadministration of proton pump inhibitors may decrease the efficacy of capecitabine in metastatic breast cancer patients

Dear Editor,

Recent retrospective data have found that coadministration of gastric acid suppressants such as proton pump inhibitors (PPIs) or histamine receptor antagonists with tyrosine kinase inhibitors (TKIs) can decrease the efficacy of erlotinib and sunitinib in advanced and/or metastatic non small cell lung cancer and renal cell cancer, respectively [1,2]. This association with gastric acid suppressants may not be limited to TKIs, given that many oral drugs like capecitabine, require a sufficiently acidic en-

vironment to properly dissolve for systemic absorption. Capecitabine is an orally taken agent commonly used in many solid tumors like metastatic human epidermal receptor 2 (HER2)-negative or -positive breast cancer patients (capecitabine or capecitabine plus lapatinib) [3]. Another study investigated the association of PPIs and capecitabine efficacy in advanced gastroesophageal cancer. Capecitabine is sensitive to gastric pH level changes in which substantial reductions in gastric acidity can lead to less drug dissolution. The authors of this study found that PPIs negatively affected capecitabine efficacy

[4]. In conclusion, the efficacy of capecitabine in metastatic breast cancer patients may be decreased during concomitant use of PPIs by possibly raising gastric pH levels, leading to altered dissolution and absorption of capecitabine. This proposal should be validated for metastatic breast patients receiving capecitabine with or without PPIs.

References

1. Chu MP, Ghosh S, Chambers CR et al. Gastric acid suppression is associated with decreased erlotinib efficacy in non-small-cell lung cancer. *Clin Lung Cancer* 2014;16: 33-39.
2. Ha VH, NgoM, Chu MP, Ghosh S, Sawyer MB, Chambers CR. Does gastric acid suppression affect sunitinib efficacy in patients with advanced or metastatic renal cell cancer? *J Oncol Pharm Pract* 2014;21:194-200.
3. Babacan T, Efe O, Hasirci AS et al. Efficacy of

capecitabine monotherapy as the first-line treatment of metastatic HER2-negative breast cancer. *Tumori* 2015;101:418-423.

4. Chu MP, Hecht JR, Slamon D et al. Association of proton pump inhibitors and capecitabine efficacy in advanced gastroesophageal cancer: secondary analysis of the TRIO-013/LOGiC Randomized clinical trial. *JAMA Oncol* 2016 Oct 13. doi: 10.1001/jamaoncol.2016.3358. [Epub ahead of print]

Kadri Altundag

Hacettepe University Cancer Institute, Department of Oncology, 06100 Sıhhiye, Ankara, Turkey

Correspondence to: Kadri Altundag, MD.

E-mail: altundag66@yahoo.com

Does EGFR targeted therapy change the natural history of EGFR mutant status?

Dear Editor,

Epidermal growth factor receptor (EGFR) is a cell surface molecule that binds epidermal growth factor extracellularly. The identification of EGFR as an oncogene has led to the development of targeted therapies. If EGFR mutation status is confirmed, it is predictive of benefit from EGFR tyrosine kinase inhibitors (TKIs) in non small cell lung cancer (NSCLC), with significant advantages compared to chemotherapy in progression free survival (PFS) and response rates in both first- and second-line. In the current clinical practice, targeted therapy with EGFR-TKI is the first-line treatment for metastatic NSCLC patients with EGFR mutation. However despite all benefits, resistance is a substantial issue [1]. Herein we present a patient whose EGFR mutation status changed after erlotinib treatment.

A 57-year-old man diagnosed with metastatic lung adenocarcinoma was referred to our hospital with EGFR exon 19 activating deletion mutation using polymerase chain reaction (PCR) in the primary tumor. As an anti-EGFR TKI therapy, erlotinib 150mg/day started orally. After 3 months of treatment, an intolerable grade 3 skin rash emerged. After brief interruption, treatment restarted with a lowered dose at 100mg/day. Both primary and metastatic lesions were stable for a 10-month period. Follow-up PET-CT imaging showed progression in the primary hilar mass with new lesions in the skeleton. Histopathological examination of control biopsy from the primary tumor site was compatible with necrosis only. EGFR gene mutations are examined in extracted DNA from plasma with QIAamp circulating Nucleic Acid Kit. No EGFR gene mutation was found this time, which means there was loss of EGFR activating mutation and there wasn't T950M secondary mu-

tation or any other mutation. The patient's performance status was ECOG 1, so single-agent pemetrexed started as second-line chemotherapy for advanced NSCLC.

Resistance can be either de novo or acquired. Some possible mechanisms for the acquired resistance have been identified, the most common being the development of an EGFR T790M 'gatekeeper' mutation in half of the cases. Other mechanisms include MET amplification, small-cell or epithelial-mesenchymal transition. In 30% of the cases, the mechanism of acquired resistance is unknown [2]. Additionally, in some studies loss of EGFR-activating gene mutations in resistant tumor samples has been reported, meaning that the mutation disappeared after treatment with consecutive chemotherapeutics and EGFR-TKIs [2,3]. In our case also, after treatment with erlotinib, there was loss of EGFR activating deletion mutation. To our knowledge, this situation can occur due to tumor heterogeneity [4,5], that causes loss of EGFR mutated clone and the emergence of EGFR wild-type clones, or discordance between EGFR mutation status in the tumor itself and plasma free-DNA. After progression in first-line therapy it may be needed a molecular assessment not only to detect the resistance mechanism, but also for anticipation of response to TKI treatment in second-line therapy.

References

1. Tetsu O, Hangauer MJ, Phuchareon J, Eisele DW, McCormick F. Drug Resistance to EGFR Inhibitors in Lung Cancer. *Chemotherapy* 2016;61:223-235
2. Honda Y, Takigawa N, Fushimi S et al. Disappearance of an activated EGFR mutation after treatment with

- EGFR tyrosine kinase inhibitors. *Lung Cancer* 2012; 78:121-124.
3. Tabara K, Kanda R, Sonoda K et al. Loss of activating EGFR mutant gene contributes to acquired resistance to EGFR tyrosine kinase inhibitors in lung cancer cells. *PLoS One* 2012;7:e41017.
 4. Bai H, Wang Z, Chen K et al. Influence of chemotherapy on EGFR mutation status among patients with non-small cell lung cancer. *J ClinOncol* 2012;30:3077-3083.
 5. Mansuet-Lupo A, Zouiti F, Alifano M et al. Intratumoral distribution of EGFR mutations and copy number in metastatic lung cancer, what impact on the initial molecular diagnosis? *J Transl Med* 2014;12:131.
- Alisan Zirtiloglu, Ibrahim Cil, Deniz Tural
- Department of Medical Oncology, Bakirkoy Dr. SadiKonuk Education and Research Hospital, Istanbul, Turkey.*
- Correspondence to:* Deniz Tural, MD.
E-mail: deniztural@gmail.com